



Red Vent Syndrome (RVS) in Wild Atlantic salmon (*Salmo salar*)



Plate 1.

Wild fish showing evidence of red vent syndrome and associated anal bleeding

Background

Since early June 2007 there have been reports from across Scotland of wild Atlantic salmon (*Salmo salar*) returning with inflamed vents. These symptoms have not been reported in farmed Atlantic salmon or sea trout (*S. trutta*) and seem to be restricted to wild Atlantic salmon populations. Investigations are being carried out by Fisheries Research Services to establish the cause and extent of the problem.

By September 2007 FRS had received notification of over 50 rivers, across Scotland, with returning Atlantic salmon that were showing signs of swollen, bleeding vents. These fish appear to be in good physical condition apart from the red vents, and have only recently returned from the sea to rivers. The vast majority of fish showing symptoms are Atlantic salmon grilse, although a small number of two sea-winter fish have been found with the condition. Both male and female Atlantic salmon are affected, but the problem has not been seen in parr or smolts.

Current investigations

There have been extensive field and laboratory investigations, and, to date, bacteriological, virological, molecular biological and serological tests have all been negative for known fish pathogens. Histological examination has found evidence of a severe dermatitis and an acute inflammatory response which accounts for the swelling around the vents.

Parasitological investigations have shown the presence of nematode worms, including *Anisakis* sp. and *Hysterothylacium* sp., in the region of the vent of all fish examined that have shown signs of RVS. These parasites can occur naturally in wild fish and are a contributory factor, or may be the primary cause of red vents, although our investigations are continuing.

External signs

Fish returning to Scottish rivers may show signs of an inflamed and bleeding vent (plate 1, see above); the



following photographs show the condition in varying degrees of severity, as well as the parasites around the vent in an histological context.

Normal vent (for comparison)

A normal vent may have a superficial redness around the urogenital opening (vent; plate 2).



Plate 2. Normal vent

Mild Lesion:

Some degree of sub-epidermal swelling and reddening around the vent has occurred (it is not a superficial redness). There is no obvious erosion of the skin but there may be some tissue swelling and/or scale loss in the general area of the vent (plate 3).

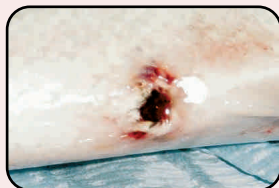

Plate 3. Swelling and scale loss around the vent

Moderate Lesion:

An obvious widespread erythema (a redness of the skin) surrounding the vent develops (plate 4) and there may be petechial haemorrhages (which appear as small red spots) around the vent. Some swelling might be seen close to the vent, and some scales may be missing.

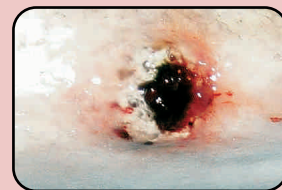


Plate 4. Widespread reddening around the vent

Severe Lesion:

There can be pronounced swelling, severe haemorrhage and scale loss. Tissue may protrude from the vent and bleeding from the lesion may occur if gentle pressure is applied (plate 5).

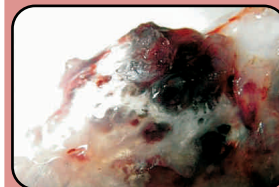


Plate 5. Prolapse with tissue protruding from the vent

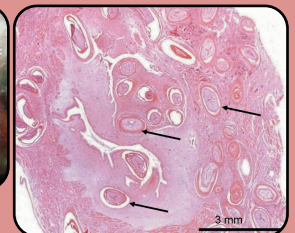


Plate 6. Histological section of a red vent showing the nematode worms (arrows) in situ (scale bar 3 mm)

Contact us

Anyone concerned about this issue or finding fish with these symptoms should contact the Fish Health Inspectorate at FRS Marine Laboratory, telephone 01224 876544 and ask for the Duty Inspector. Alternatively e-mail: fishhealth@marlab.ac.uk